

# Multiple Endocrine Neoplasia 1: Providing Care for the Family

Suzanne M. Mahon, RN, DNSc, AOCN®, APNG, and Laura Waldman, MS

Multiple endocrine neoplasia 1 (MEN1) is a hereditary syndrome associated with a number of endocrine and nonendocrine tumors. Unfortunately, a diagnosis of MEN1 often is delayed until after the patient has developed an advanced or second MEN1-related tumor. Nurses need to be familiar with hallmark signs of this syndrome to facilitate an early diagnosis and appropriately refer families for genetic assessment and, ultimately, develop a long-term plan for early detection and intervention for all family members at risk for MEN1.

B.T., a 38-year-old woman, initially presented to her primary care physician with a six-month history of abdominal pain and diarrhea, which she had been attributing to stress because of her recent divorce. A subsequent upper endoscopy revealed duodenal ulcers and a computed tomography scan of the abdomen showed a 3 x 4 cm mass near the pancreatic head. She also had an elevated fasting serum gastrin level. Exploratory surgery showed three duodenal masses, all of which were excised. Pathology reported that all of the duodenal lesions were consistent with gastrinoma. B.T. was then referred to the oncology clinic to discuss prognosis and possible treatment options.

## Nursing Assessment and Physical Examination

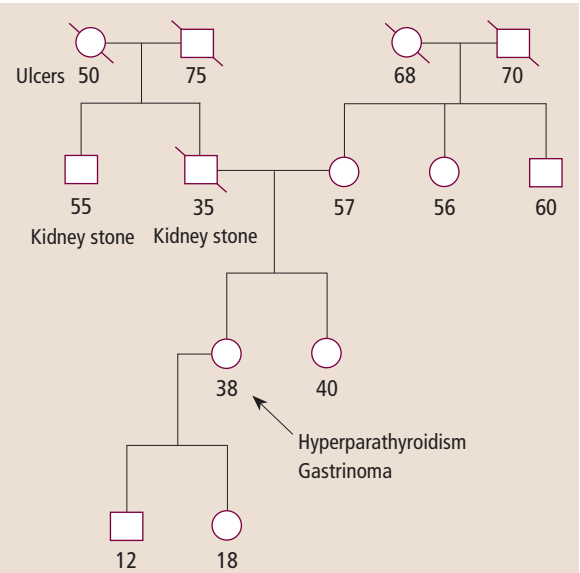
On assessment, the nurse reviewed B.T.'s past medical and family history. B.T. had a history of hypercalcemia caused by hyperparathyroidism for which she underwent a subtotal parathyroidectomy at age 25. B.T. also reported a one-year history of oligomenorrhea. Review of the family history reveals that B.T.'s father and paternal uncle had a history of kidney stones. Her father died at the age of 35 in a motor vehicle accident. B.T. had limited information about her father's family history, but her paternal grandmother died of "stomach ulcers" (see Figure 1). On physical examination, B.T. is noted to have six facial cutane-

ous tumors (angiofibromas) that she states "have always been there." The remainder of her physical examination is unremarkable. B.T. is a grocery store cashier and a single parent. She has a 12-year-old son and an 18-year-old daughter. She expresses to the nurse that she is very concerned about the impact of her recent diagnosis on her children.

In B.T.'s case, the history of hyperparathyroidism and gastrinoma are classic clinical features of multiple endocrine neoplasia 1 (MEN1) (see Figure 2). Her initial diagnosis of hyperparathyroidism together with the family history of kidney stones and an ulcer were previously unrecognized red flags for MEN1.

Given the family and medical history, B.T. was referred for a genetic assessment and was found to have an MEN1 mutation. Subsequent biochemical testing revealed elevated prolactin levels as well as elevated parathyroid hor-

monone and serum calcium levels. Magnetic resonance imaging showed a pituitary adenoma. B.T. was referred to an endocrinologist for management of the pituitary tumor and recurrent hyperparathyroidism.



Note. Circle = female, square = male, slash = deceased. The arrow points to the proband who was the first individual tested in this family. The proband developed hypercalcemia from hyperparathyroidism and underwent a subtotal parathyroidectomy. The proband subsequently developed a gastrinoma.

Figure 1. Pedigree of B.T.'s Family

Suzanne M. Mahon, RN, DNSc, AOCN®, APNG, is a clinical professor in the Division of Hematology/Oncology and Laura Waldman, MS, is an assistant clinical professor in the Division of Medical Genetics, both in the School of Medicine at Saint Louis University in Missouri.

Digital Object Identifier: 10.1188/10.CJON.657-660